

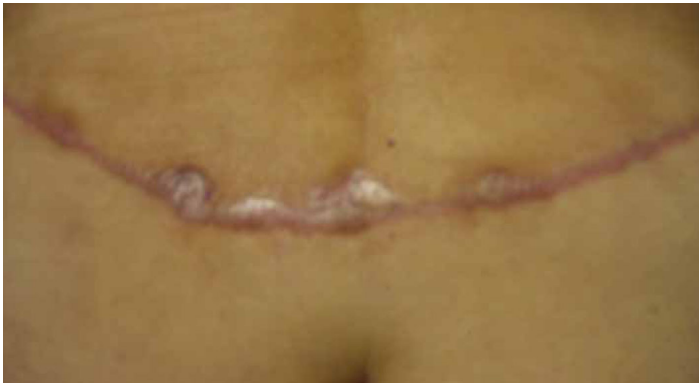

Fig 10 – (Left) Three weeks post abdominal belt lipectomy. Evidence of hypertrophic scarring. (Right) Results after 8 weeks of treatment with slide-on applicator on the left side and right side serving as control.

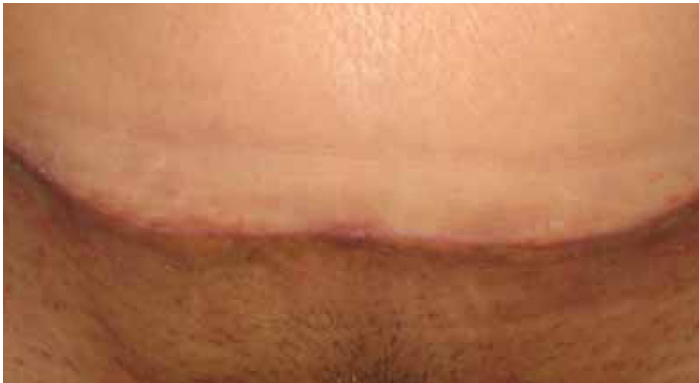
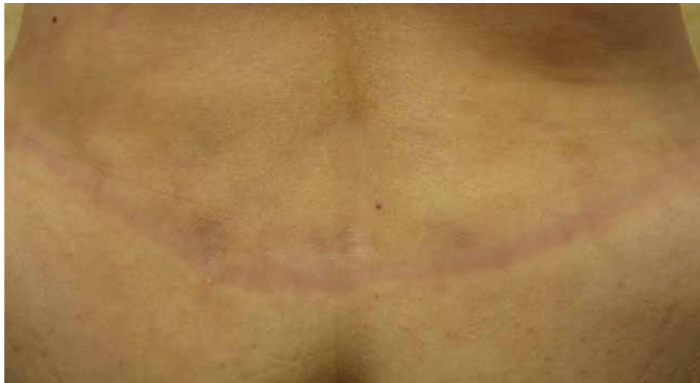
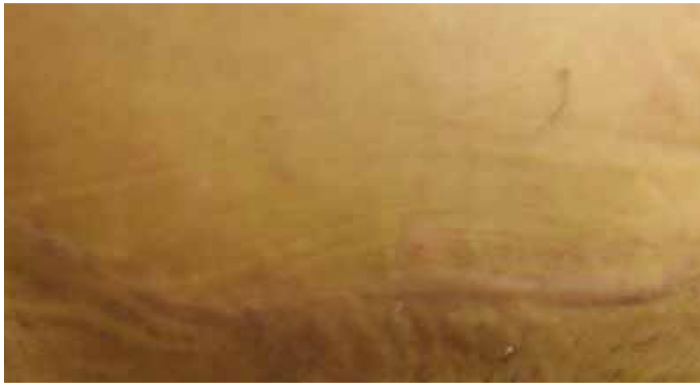Fig. 11- (Left) Four weeks after an abdominoplasty with previous history of hypertrophic scarring . Scar in the left hemi abdomen received topical treatment with slide-on applicator of silicone and the contralateral side was used for control. (Right) Results after 12 weeks of treatment.



## DISCUSSION

Initial findings are overwhelmingly positive with regard to patient satisfaction and compliance with the slide-on silicone gel applicator, Pro-Sil. Its compact size combined with a convenient familiar

container design (lipstick look alike ) reflected a more practical and convenient delivery mechanism of topical polydimethylsilicone.

## CONCLUSION

100% of the patients preferred the use of the slide-on applicator over the silicone sheets. Although the results of the local effects of topical silicone gel in multiple hypertrophic scars and keloids are comparable despite the delivery mechanism used, the ease, practical-

ity and convenience of using the slide-on applicator makes us feel very optimistic to recommend this device over any other technology currently available on the market today.

## REFERENCES

1 - Van de Kar L.A., Corion,L.U., Smeulders J.C., Draaijers L. J., Van der Horst C.M. Van Zuijlen P. P., Reliable and Feasible Evaluation of Linear Scars by the Patient and Observer Scar Assessment Scale. Plast. Reconstr. Surg.116, 514, 2005.  
2 - Niessen F.B., Spauwen P.H., Schalkwijk, J., and Kon M., On the nature of hypertrophic scars and keloids. A review. Plast. Reconstr. Surg. 104:1435, 1999.  
3 - Deitch, E.A., Wheelahan, T. M., Rose, M.P., Clothier, J., and Cotter, J.,

Hypertrophic burn scars: Analysis of variables. J. Trauma 23:895, 1983.  
4 - Draaijers, L., Botman, Y. A., Tempelman, F. R., Kreis, R.W., Middelkoop, E., and Van Zuijein, P.P., Skin elasticity meter or subjective evaluation in scars: A reliability assessment.Burns 30: 109, 2004.  
5 - Teat, L., Clinical evaluation of scars. Wound Repair Regen. 10:93, 2002.  
6 - Draaijers, L.J., Tempelman, F.R., Boutman, Y.A. et al. The Patient and Observer Scar Assessment Scale: A reliable and feasible tool for scar evaluation. Plast. Reconstr. Surg.109:1108, 2002.

# PROMINENT SCAR THERAPY: SLIDE-ON APPLICATOR VERSUS TRADITIONAL SHEETS OF TOPICAL POLYDIMETHYLSILICONE FOR THE REDUCTION OF HYPERTROPHIC SCARS AND KELOIDS.



Amado Ruiz-Razura, MD, FACS, FICS • Christopher K. Patronella, MD, FACS, FICS  
German Newall, MD, FACS, FICS • Henry A. Mentz, MD, FACS, FICS • Patricia Orozco, MD

Hypertrophic scars and keloids are common fibrotic conditions that result in an over-deposition of collagen in the skin, producing itching, pain, functional limitations and disfigurement with emotional alterations and psychological consequences. Sometimes in spite of the etiology, age, size, race, location, suturing technique or wound treatment, this type of scar tissue forms even with a careful, well planned, tension free, skin repair (1). It has been reported that the mechanism of action of topical Polydimethylsilicone consists in regulating the expression of growth factors (2) by decreasing the action of fibroblasts and fibrogenic cytokines. In difficult cases the combination of massage, pressure therapy, steroids and ultrasound radiation has given suboptimal results in the treatment of prominent and difficult scars.

## OBJECTIVES

Present our clinical experience with the treatment of multiple hypertrophic scars and keloids using two delivery systems of topical Polydimethylsilicone . These are the results of the first in a series of case studies.

## MATERIALS & METHODS

Thirty-nine patients have been enrolled in this on-going clinical protocol. The study presents 30 patients, 86.6% were female and 13.4% were male. They completed the study according to specific guidelines set in the protocol with a minimum of 4 weeks of uninterrupted treatment and close follow up. Subjects were recruited from the Aesthetic Center for Plastic Surgery, a fully accredited (AAAASF) and Texas Department of Health certified outpatient facility. All patients gave informed consent. The average patient being thirty-six years old and receiving treatment from May 2005 to November 2006. Topical polydimethylsilicone gel was administered by two mechanisms: Device number one (Experimental) involved a slide-on silicone gel applicator called Pro-Sil, manufactured by Biodermis. Las Vegas, NV. USA ( See Figure Num 1) and device number two, applying the traditional delivery method (control) using topical reusable silicone gel sheets, also manufactured by Biodermis, Las Vegas. NV. USA. (Figure Num 2 )

Fig. 1- Slide-on silicone gel applicator (Biodermis. Las Vegas. NV. USA )

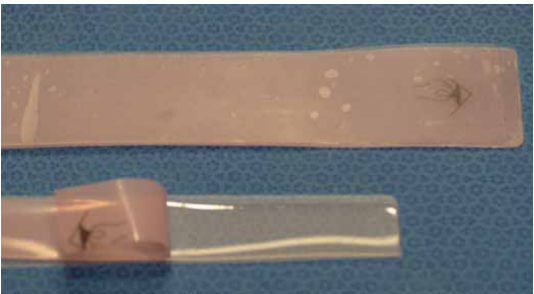
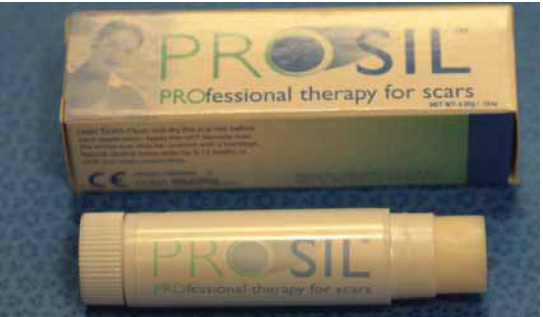

Fig 2- Traditional silicone sheets applied over prominent scars.

A separate scar lesion located within the same anatomical area in the same patient served as control when patients refused to wear the topical sheets. Special attention was given to the scar size, thickness, height, and color. Lesions included recent and old scars, post surgical wounds, keloids and hypertrophic scars secondary to traumatic injuries. Silicone sheets were re-washed and worn for a minimum of 12 hours a day for 8-12 weeks. They were cut to cover only the area of the scar. With the slide-on applicator the patient was asked to apply a single pass of the product over the scar 3 times a day for 8-12 weeks. Photographic documentation of the scar was used to record the characteristics before and after treatment.

Scars were assessed by three independent observers using the observer scale to evaluate vascularity, pigmentation, thickness, relief, pliability and surface area. The patients evaluated their scars simultaneously, at 0, 6, and 12 weeks later using the patient scale (1,6) for the evaluation of the following parameters: color, stiffness, thickness, and relief. Patients, nursing staff and surgeons gave an evaluation of the scar and assessment was based using the Patient and Observer Scar Assessment Scale (1).



MATERIALS & METHODS (CONT.)

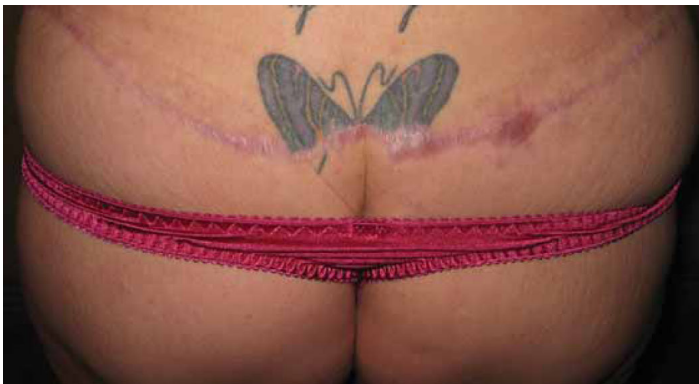

Fig. 3 – 19 year old patient 1 month after abdominal belt lipectomy presents with incisional hypertrophic scars in the back. She receives topical Polydimethylsilicone treatment with the slide-on applicator on her right side and the application of topical silicone sheets on her left side.

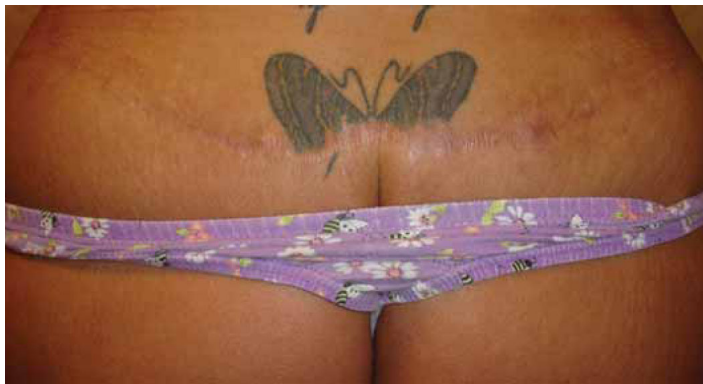

Fig 4 – Same patient after receiving treatment. Results after 8 weeks of uninterrupted therapy. Note how the scar has changed in color, width, elevation and consistency.

RESULTS

A total of 26 females and 4 males were included in the study. The scar age ranged from 2 weeks to 16 years. 12 were Caucasian, 9 Hispanics, 7 African American and 2 Asians. The scars were located in the breasts (18) abdomen (8) in the chest (5) in the back (4) and arms (3). The mean scar size was 40.2cm.

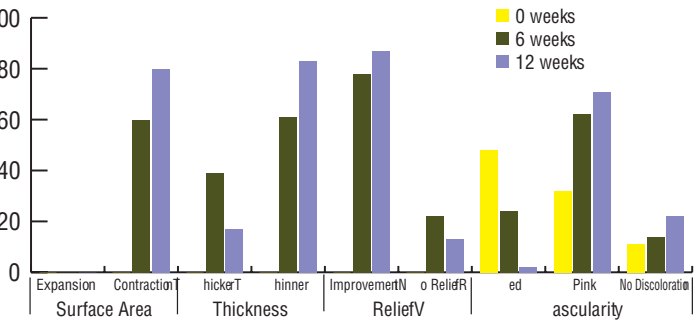
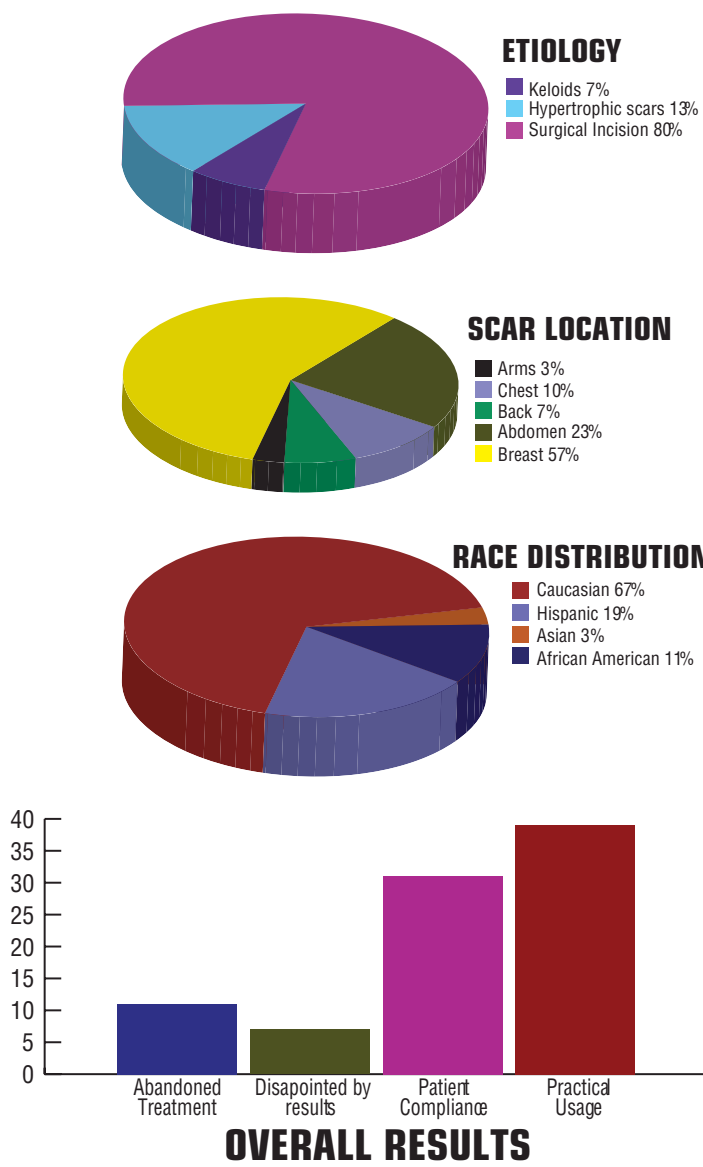


Fig 5 – Scar Assessment at 0, 6, and 12 weeks after topical application of polydimethylsilicone.

The assessment scale indicated comparable scar results with the application of topical Polydimethylsilicone using either delivery system. However, there was a substantial difference in the preference by the patient for the use of the slide-on applicator than for the traditional silicone sheets. The following are pictures of some of the patients included in this study, before and after treatment.



Treatment was difficult to follow after 4 weeks in 11 patients that ultimately abandoned the use of the traditional sheets. They felt that the use of the silicone strips was cumbersome, messy, would not adhere properly to the skin, would roll, and get dirty after a short usage.

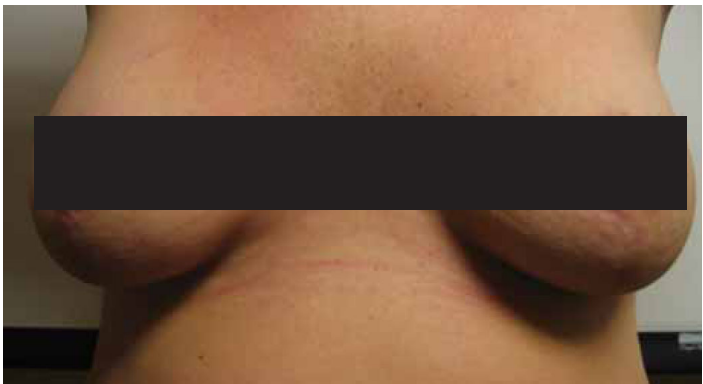
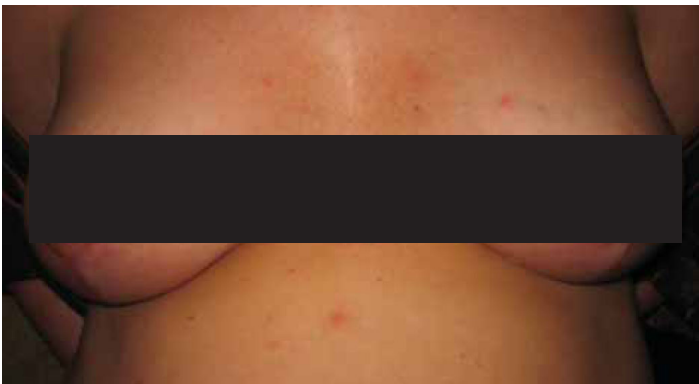
Fig 6 – (Left) Two weeks post reduction mammoplasty. Patient initiates therapy with slide-on applicator to the right breast and topical sheets to the contralateral breast. (Right) Result at 8 weeks.

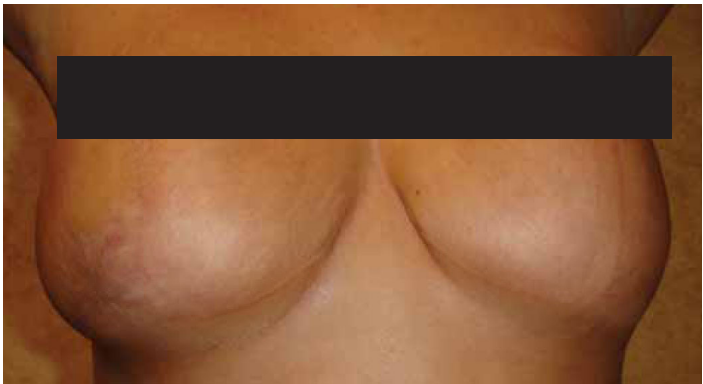
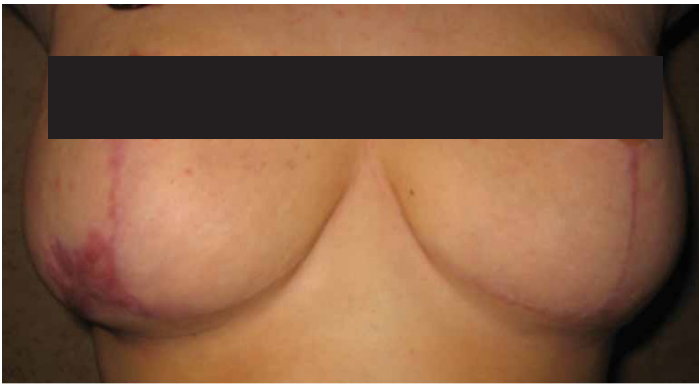

Fig 7 – (Left) Wound dehiscence of right breast with hypertrophic scarring at two weeks after breast reduction. Right breast received topical Polydimethylsilicone (slide-on applicator) and left breast served as control. (Right) Result at 10 weeks after treatment.

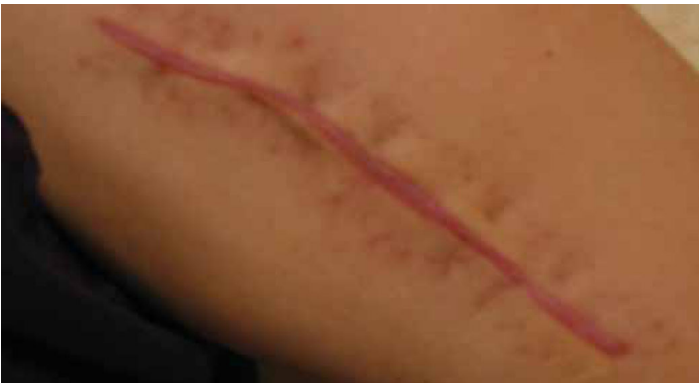

Fig 8 – (Left) 2 weeks post incisional wound of left fracture of the Humerus. Half of proximal length of the incision received treatment with the slide-on applicator and the distal length served as control. (Right) Result at 6 weeks post treatment.

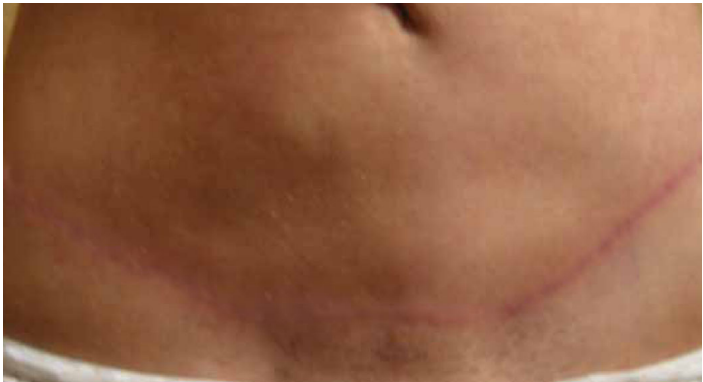
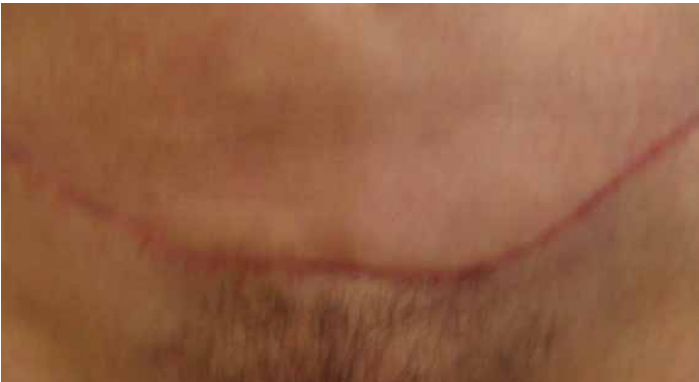
Fig 9 – (Left) 4 weeks after abdominoplasty. Right abdominal incision treated with slide-on applicator and contralateral side with traditional sheets. (Right) Results at 8 weeks indicates improvement more evident with the slide-on applicator than with the topical sheets.